

118189

J.N.M

Hospital

KLY

Health District,

NADDA

District

Voucher for Free Services from PPP Diagnostic Lab

Patient Name: M. A. Mondal Age: 21 Sex: M

Address: Chakdaha

Register Id: 8628 Date: 25/08/18

Received the services and I have not paid any amount for the service.

Muhsed Ahammad Mondal

Signature of the Patient

Superintendent

Hospital

Health District,

District

# J. N. M. HOSPITAL, KALYANI

ELECTRO THERAPUTIC DEPARTMENT (X-RAY)

Name..... M. A. Mondal ..... Age 21 ..... Sex M .....

Address.....

Physician/Surgeon..... Ward Ward (D) .....

No. of Bed Cabin..... Paying / Non-Paying.....

Brief history of case

Clinical Diagnosis  
Particular Point to be investigated.  
Instruction

MRI - L-S - Spine

Date- 28/8/18

Med. Signature

[Signature]  
College of Medicine & J.N.M. Hospital  
W.B.U.H.S  
Kalyani, Nadia

**REPORT**

67 kg  
2658  
@kardake  
7065711398

250



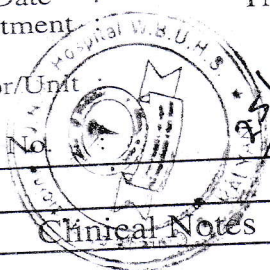
**COLLEGE OF MEDICINE & JNM HOSPITAL  
WEST BENGAL UNIVERSITY OF HEALTH SCIENCES  
KALYANI, NADIA, PIN - 741 235**

MALE ORTHOPEDIC 19

User Name : BIDYUT  
Email : Bidyut@wbuhs.ac.in

Name : MASAD AHAMAD MONDAL Regd. No. : JNM/REG/1800090620 Day : Saturday  
 Sex : Male Age : 21 Yrs. 0 Months 0 Days Reg. No. : JNM/REG/1800090620  
 Ref. From : Reg. Date : 11-08-2018 Card No. : JNM/DOR/1800090317  
 Visit No. : 1 Department : MALE ORTHOPEDIC Visit Date : 11-08-2018 Time : 09:22AM  
 Doctor/Unit Name (DOW) : DEJAY KUMAR/DI TUSHAR KANTI GHARAI Entry No. :  
 Room No. :

Visit No. : 2 Visit Date : TM. Department : Doctor/Unit : Entry No. :	Visit No. : 3 Visit Date : TM. Department : Doctor/Unit : Entry No. :	Visit No. : 4 Visit Date : TM. Department : Doctor/Unit : Entry No. :
---	---	---



**Clinical Notes**

**ADVICE**

11/8  
 → LBP & pain  
 over B/L legs  
 for last 4 months  
 → X-ray L5 spine  
 showing  
 9 Rudimentary ribs  
 seen in L<sub>5</sub>  
 → ↓ disc space  
 seen at L<sub>4</sub>-L<sub>5</sub> level  
 suggesting degenerative  
 disc disease at  
 L<sub>4</sub>-L<sub>5</sub> level.

T. Pam (500/650) Acp- 1 tab. BDPC x 7 d  
 T. I buprotan(200/400)-  
 T. Fm (20/40) Rab 20 Antacid 1 tab ODAC x 7 d  
 T. Pan (40/D) omez (20)-  
 T. Coamony elcv (625/375)-  
 T. Vit BC- 1 tab ODAC x 5 d  
 T. cifran (500/250)-  
 → Tab. Gabapentin + NT (400/10) 1 tab. OD HS  
 x 1 m.  
 → Tab. Tendorman 1 tab. ODAC x 10 d.  
 → ~~Tab.~~

T. Pam (500/650) Acp- 1 tab. BDPC  
 T. I buprotan(200/400)-  
 T. Fm (20/40) Rab 20 Antacid  
 T. Pan (40/D) omez (20)-  
 T. Coamony elcv (625/375)-  
 T. Vit BC-  
 T. cifran (500/250)-  
 08/11/2018 09:23 AM

25/8/18  
 PUC of LBP

→ MRI - L<sub>5</sub> spine  
 → Tab. Fejuna OD x OD  
 → Tab. Pregabalin x OD HS x 10