

# R. G. KAR MEDICAL COLLEGE & HOSPITAL

## Electro Therapeutic Department

Report / Treatment is required of

Name Abdul Kalam Age 45y Sex M

Address .....

Physician / Surgeon Surgery V-III Ward CBABS No. of Bed / Cabin M35

Paying / Non Paying Gen

Brief history of case CBCT - Bilobar IHBR are dilated without formation

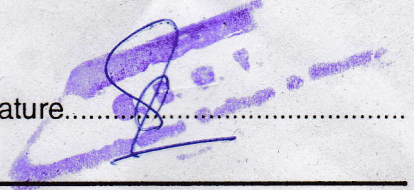
Clinical Diagnosis of primary confluence. Mild wall thickening of

Particulars point to be Investigated common hepatic duct with significant

Instruction

Date 09/10/18

MRCB

Signature 

**REPORT**